

# Uterine Artery Embolization

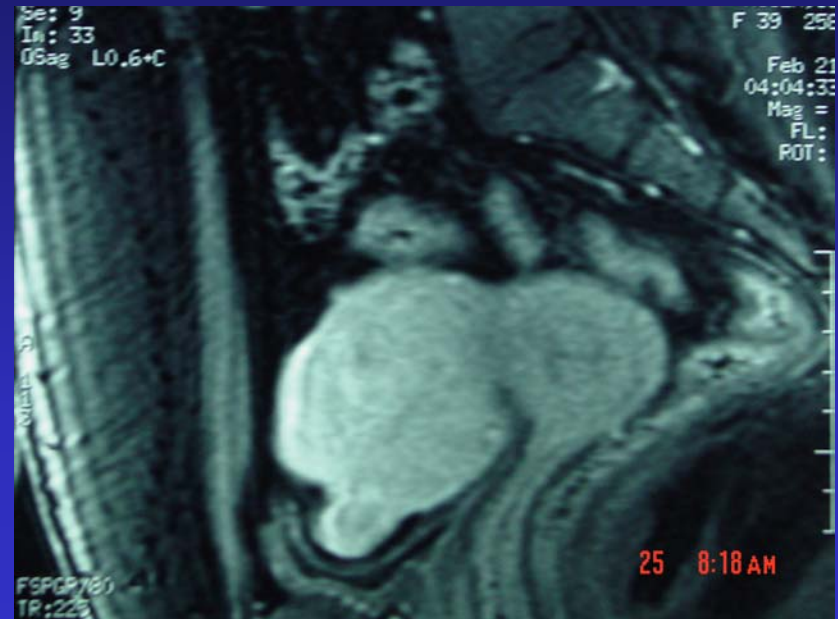
---

- History: 40 year old female with pelvic pain and dysmenorrhea. Multiple large uterine fibroids.
- Treatment: Bilateral uterine artery embolization.
- Recovery: Home in two days.
- Outcome: Complete resolution of symptoms.

# Uterine Artery Embolization

## Initial MRI of Pelvis

- **Sagittal image of uterus**
- **Note large fibroids and compression of urinary bladder**

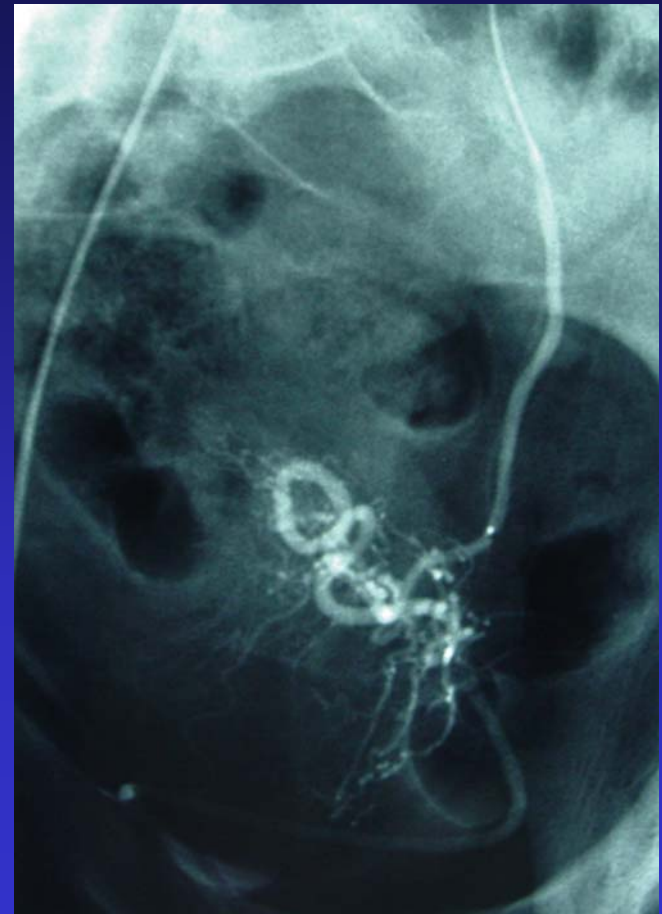


# Uterine Artery Embolization

---

## Angiogram and Embolization

- **Catheter in uterine artery**
- **PVA particles about to be injected**

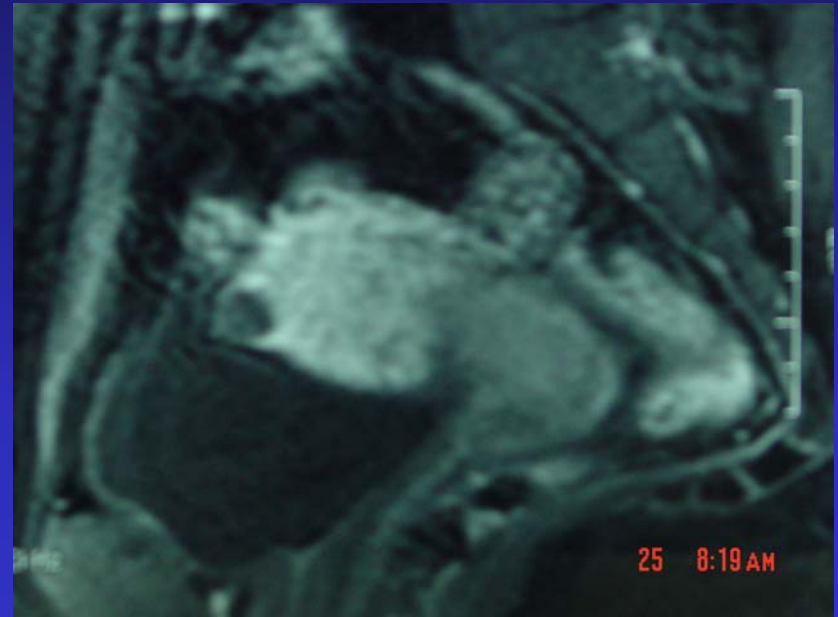


# Uterine Artery Embolization

---

## 3-month post MRI

- Note dramatic shrinkage of uterus
- Note dramatic shrinkage of fibroids and relief on urinary bladder



# Uterine Artery Embolization

## Before and After Comparison

