

# Traumatic Rupture of SFA Branch

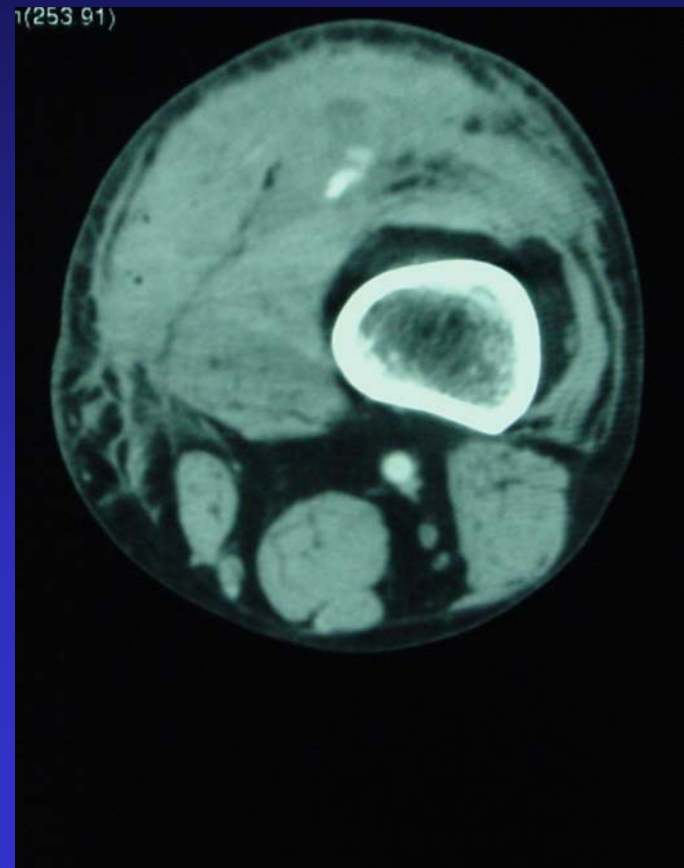
---

- History: 51 year-old man in chain saw mishap. CT reveals active bleeding into quadriceps muscle
- Treatment: Coil embolization. Closure of wounds.
- Recovery: Home the same day.
- Outcome: Complete resolution of symptoms

# Traumatic Rupture of SFA Branch

---

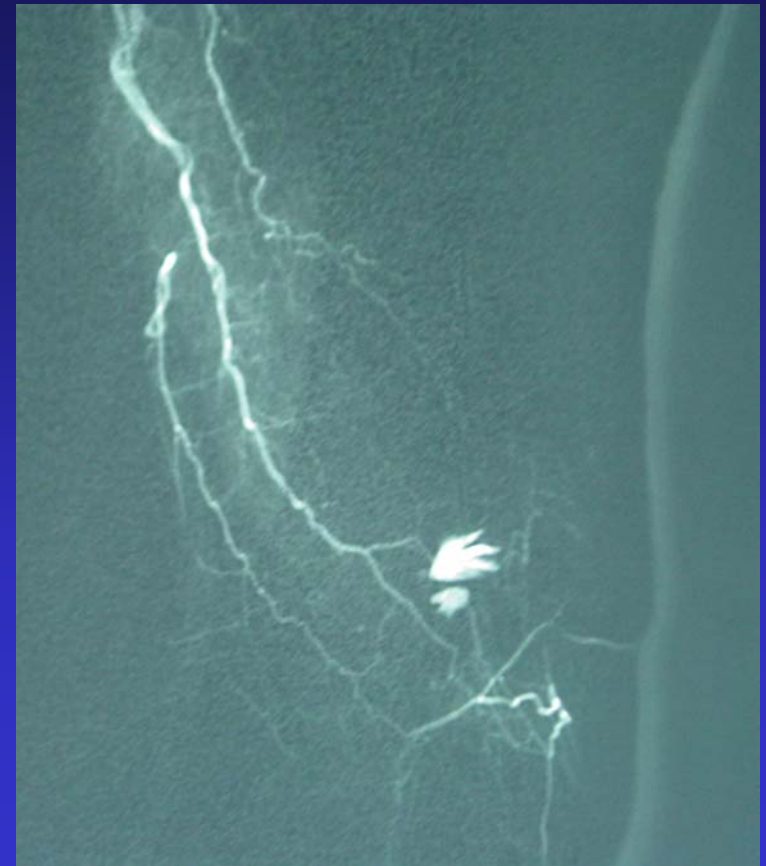
- **CT reveals active extravasation of contrast into quadriceps hematoma**



# Traumatic Rupture of SFA Branch

---

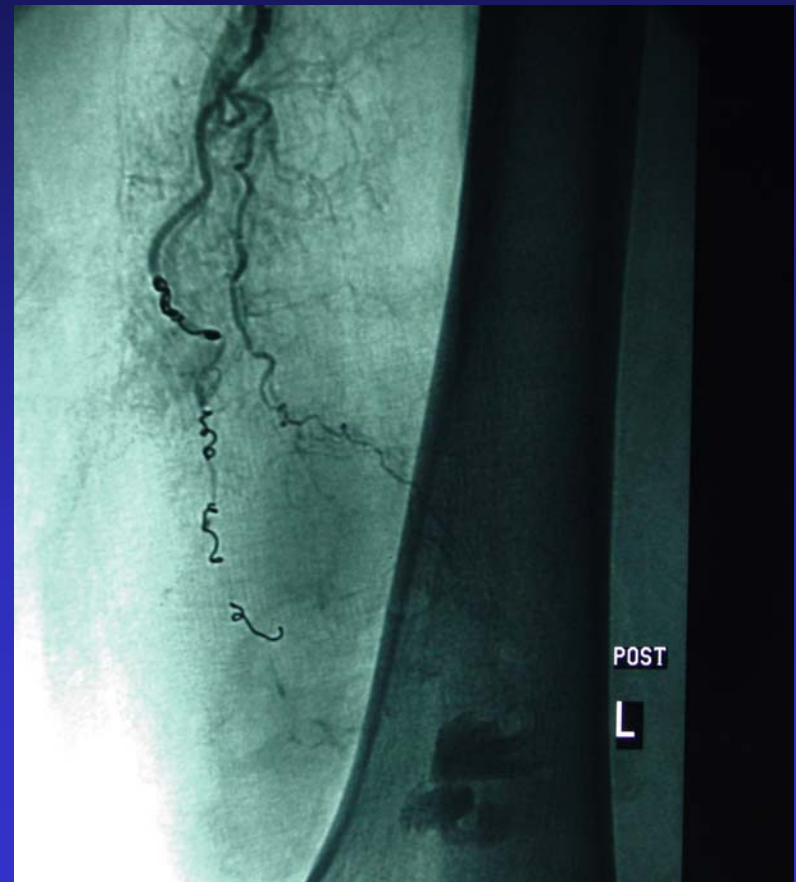
- **Angiogram reveals active extravasation from a branch of the superficial femoral artery**



# Traumatic Rupture of SFA Branch

---

- **Multiple coils placed directly into branch to stop the bleeding**



# Traumatic Rupture of SFA Branch

---

## Before and After Comparison

