

# Occluded Common Iliac Artery

---

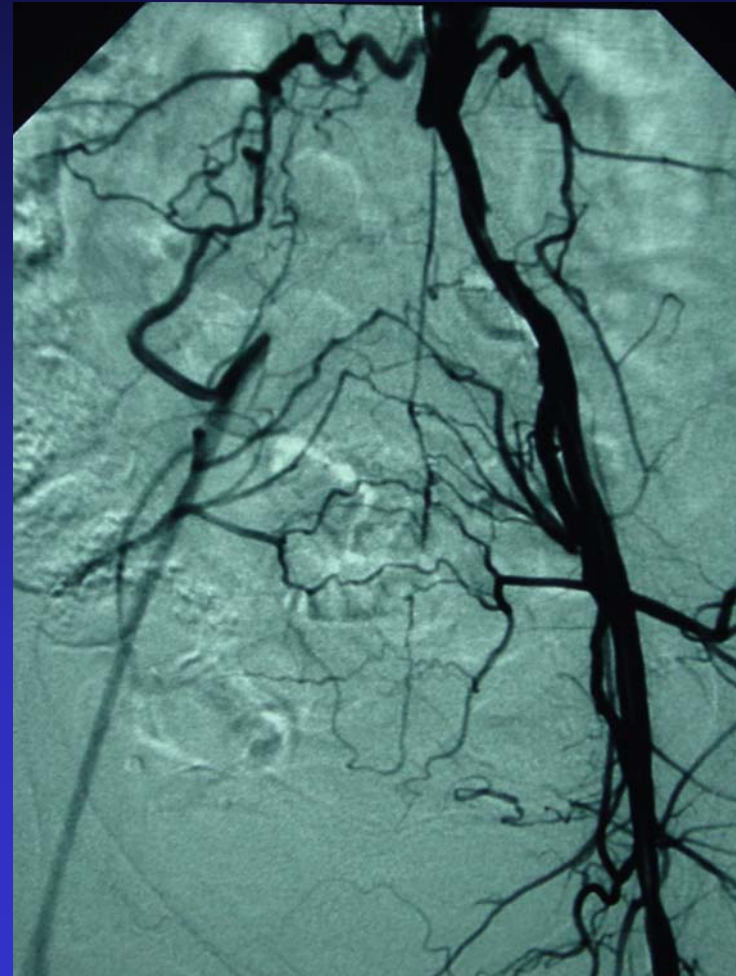
- History: 72 year-old woman with cold right leg. Angiogram reveals occluded right common iliac artery.
- Treatment: Thrombectomy, PTA and stent placement.
- Recovery: Home the same day.
- Outcome: Complete resolution of symptoms

# Occluded Common Iliac Artery

---

## Initial Angiogram

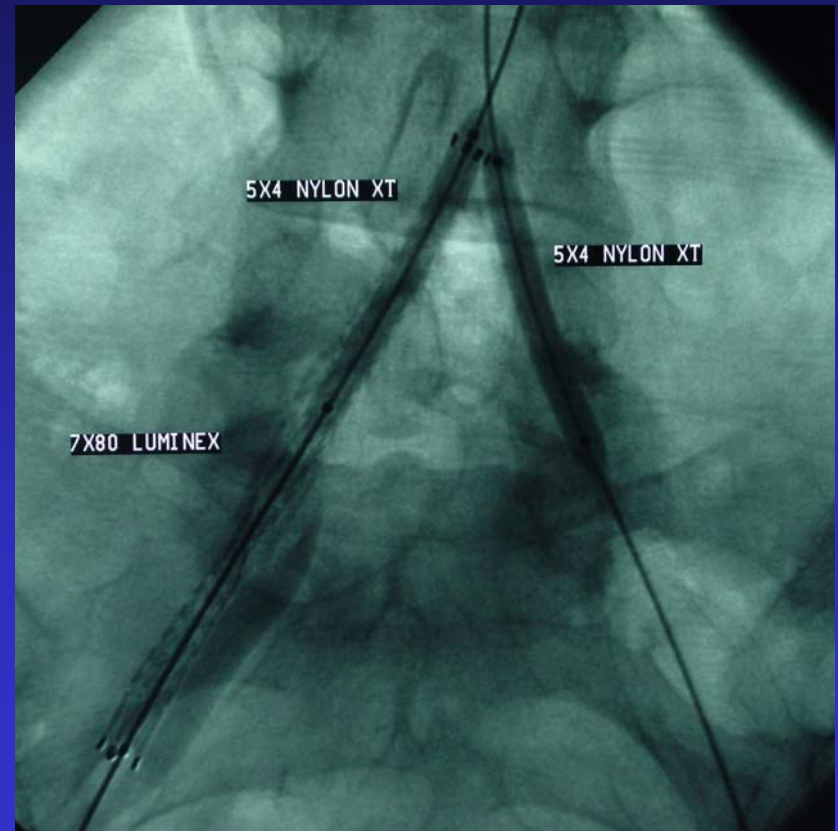
- **Note complete lack of flow in the right common iliac artery**
- **Collaterals from lumbar arteries reconstitute the right external iliac artery**



# Occluded Common Iliac Artery

## Stent Placement

- **Mechanical thrombectomy was performed**
- **Stents were placed in diseased right common iliac artery**
- **Ballon inflated in left common iliac artery for protection**



# Occluded Common Iliac Artery

---

## Before and After Comparison

