

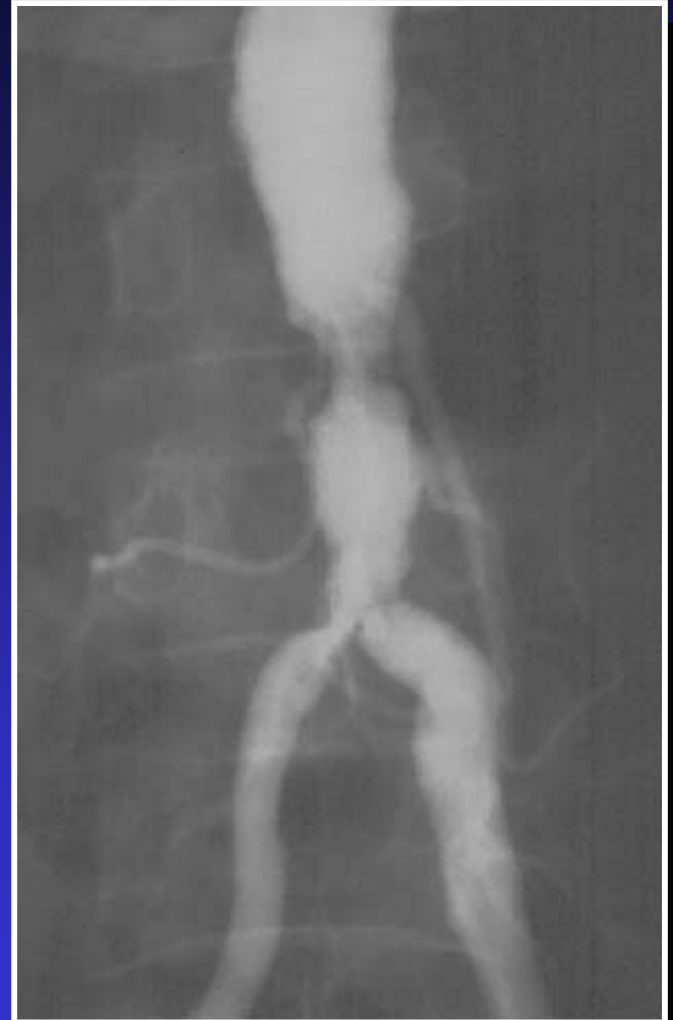Aorto-Iliac Stenosis

- History: 57 year old male with buttock and thigh claudication
- Treatment: bilateral “kissing” iliac stents and aortic PTA
- Recovery: home the same day
- Outcome: complete resolution of symptoms

Aorto-Iliac Stenosis

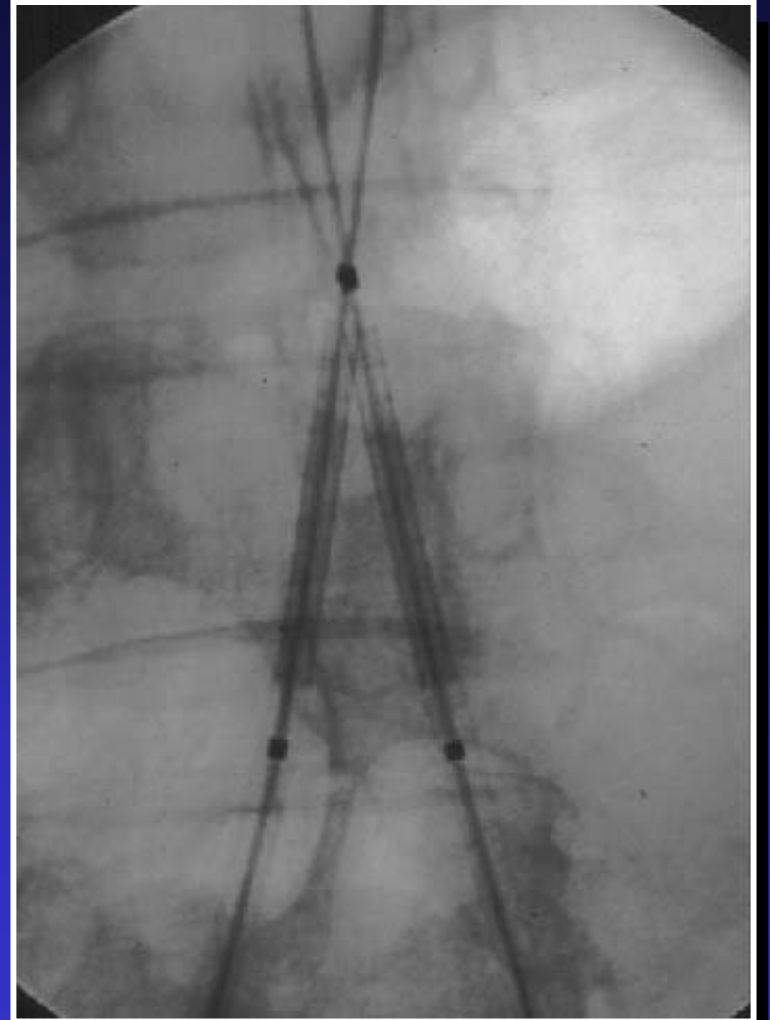
Initial Angiogram

Note lesion of aorta and both common iliac arteries.



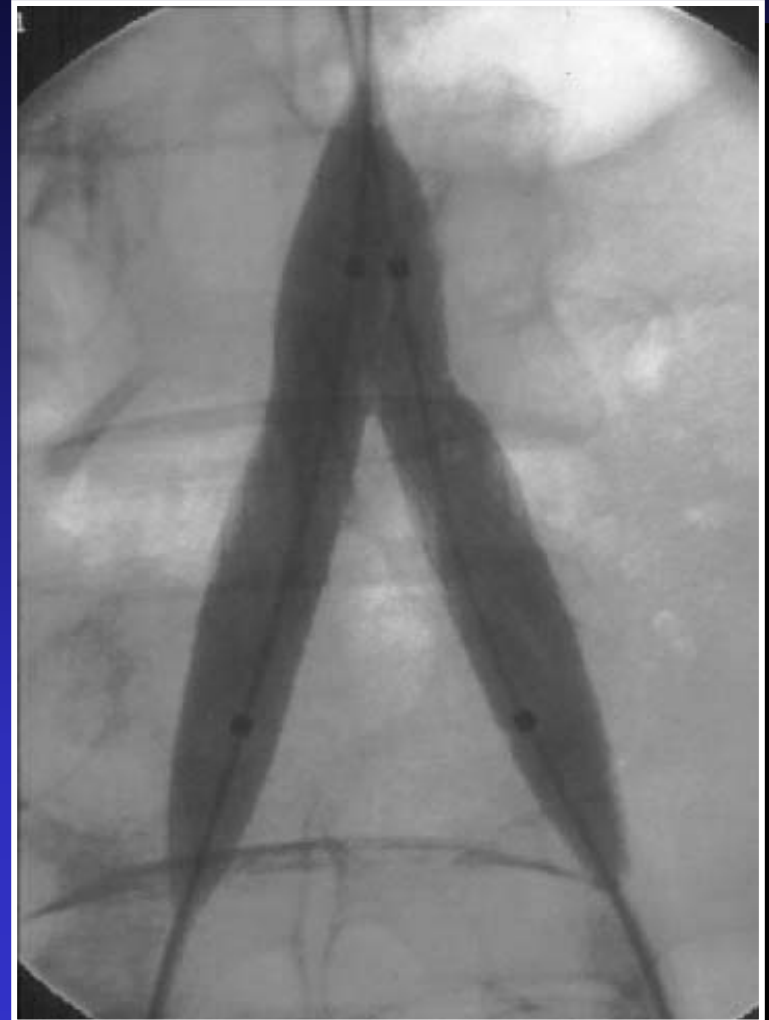Aorto-Iliac Stenosis

Kissing Stents



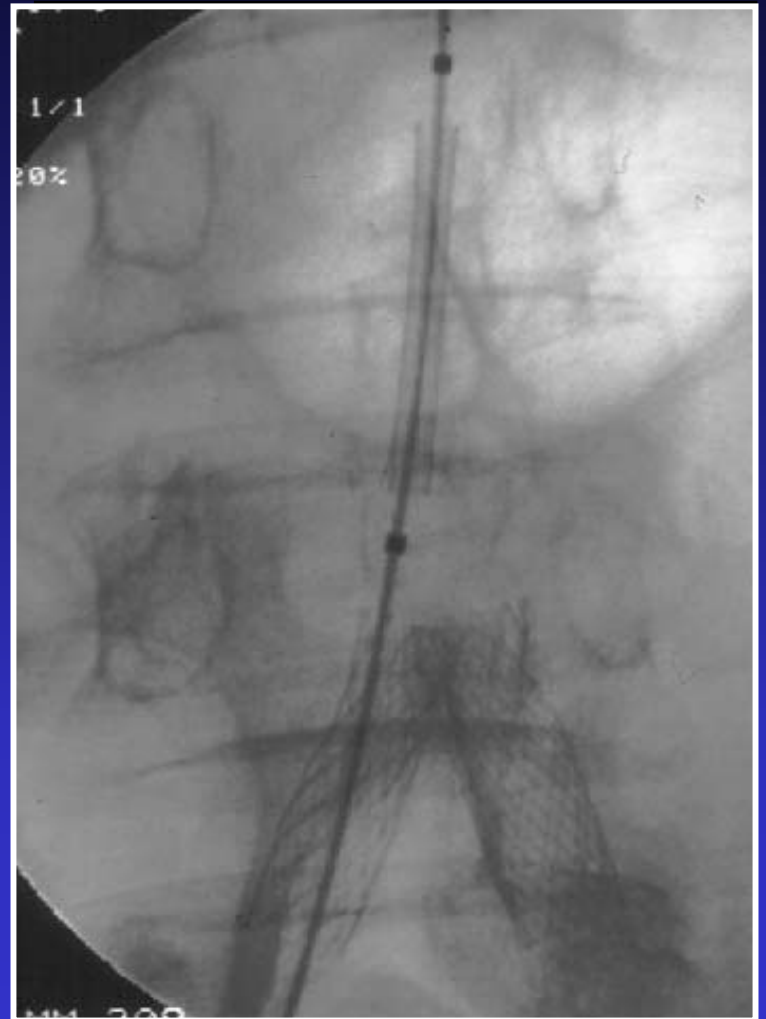Aorto-Iliac Stenosis

Stents Deployed



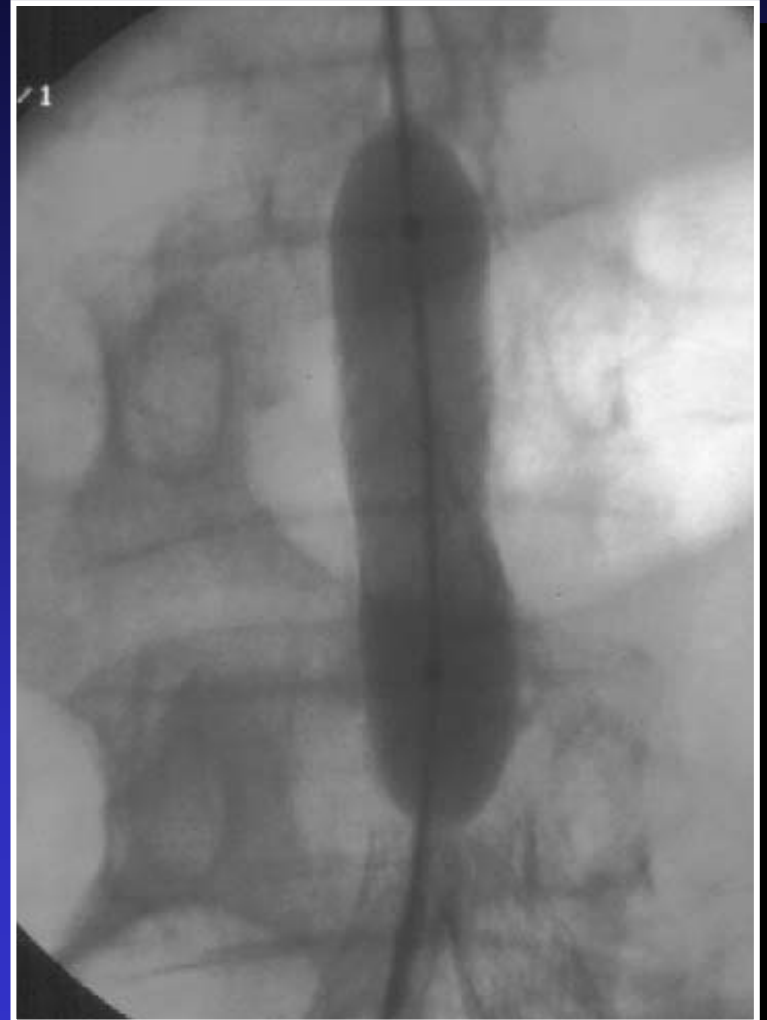Aorto-Iliac Stenosis

*Balloon Placed
in Aorta*



Aorto-Iliac Stenosis

Balloon Inflated



Aorto-Iliac Stenosis

Before and After Comparison

